



Early whole-body CT for treatment guidance in patients with return of spontaneous circulation after cardiac arrest

S. Viniol¹ · R. P. Thomas¹ · A. M. König¹ · S. Betz² · A. H. Mahnken¹

Received: 11 June 2019 / Accepted: 22 August 2019
© American Society of Emergency Radiology 2019

Abstract

Purpose Non-traumatic cardiac arrest (CA) and return of spontaneous circulation (ROSC) after cardiopulmonary resuscitation (CPR) are often associated with multiple pathologies. Expecting a high prevalence of important findings, a whole-body CT (WBCT) could be of relevance for therapy. The aim of this study is to investigate the feasibility and diagnostic yield of an early WBCT in this setting.

Methods This single-center retrospective study included 100 consecutive patients (27 female; 73 male; mean age 68.5±12.57 years) with non-traumatic, in- and out-of-hospital CA and ROSC following CPR, who underwent a contrast-enhanced WBCT within 6 h after ROSC over 12 months. CT findings were determined corresponding to anatomical region.

Results Early WBCT was successfully carried out in 100% of the patients with CA and ROSC after CPR. Acute pathologies were found not only in the chest but also in the head (15%) and the abdomen (6%). Early global brain edema ($n = 12$), acute stroke ($n = 3$), pulmonary embolism ($n = 10$), pneumothorax (26%), acute abdominal pathologies ($n = 6$), iatrogenic bleeding (4%), and CPR-related injuries (93%) were detected by CT right from the beginning of the post-cardiac arrest care.

Conclusions An early WBCT is feasible and provides added diagnostic value for patients with ROSC after non-traumatic CA.

Keywords Early whole-body CT · Cardiac arrest · ROSC · Emergency radiology

Introduction

Cardiac arrest (CA) is a major public health problem and is estimated to cause 15–20% of all deaths with an annual incidence of 98.1 per 100,000 person-years in North America. Coronary heart disease (CHD) is the most frequent underlying cause of CA followed by cardiomyopathies, inherited arrhythmia syndromes, and valvular heart diseases. Despite several major advances in cardiopulmonary resuscitation (CPR) and post-resuscitation care for out of hospital cardiac arrest (OHCA) patients, overall survival rates remain poor with near about 10% [1].

Previous data focused frequently on cardiac causes of OHCA in the last decades [2, 3]. Conversely, little is known about non-cardiac causes, for example, intracranial

hemorrhage, pulmonary embolism, or aortic dissection. In addition, CPR itself can cause life-threatening pathologies, for example tension pneumothorax, bleeding, or hemopericardium when detected and are treated too late [4].

These problems are major challenges for physicians in the emergency department because this patient group quickly needs treatment. A strategy to challenge this circumstance is to perform an early whole-body computer tomography (WBCT). Similar to a WBCT in multiple trauma patients, a WBCT in CA patients with ROSC after CPR could provide a quicker and more complete overview of life-threatening pathologies compared to a standard workup with radiographs, ultrasound, and focused CT imaging [5].

Currently, the American and European guidelines recommend focal CT imaging of CA patients with a high pretest probability of pathologies, which commonly includes a cranial CT or a thoracic CT after invasive coronary angiographic evaluation [6, 7]. According to the European guideline, WBCT may be indicated in patients with traumatic CA or hemorrhage but is not generally recommended for non-traumatic CA patients with ROSC after CPR [7]. Nevertheless, WBCT is performed more and more nowadays [4, 8, 9]. Benefits of comprehensive early imaging

✉ S. Viniol
viniol@staff.uni-marburg.de

¹ Department of Diagnostic and Interventional Radiology, Marburg University Hospital, Philipps-University, Marburg, Germany

² Department of Emergency Medicine, Marburg University Hospital, Philipps-University, Marburg, Germany

seem to be relevant, but little is known about the feasibility and the added value of such an early WBCT. The aim of this study is to investigate the feasibility and diagnostic yield of an early WBCT in this setting.

Methods

This retrospective single-center study was approved by the local ethical committee. Data were acquired between January and December 2016. The inclusion criteria were in- or out-of-hospital CA with ROSC after CPR without a traumatic cause of CA. The study included all consecutive CA patients, who underwent a complete WBCT protocol within 6 h after ROSC.

Study data were collected from the German resuscitation register (Deutsches Reanimationsregister, <https://www.reanimationsregister.de>) and radiological information system (Orbis, AGFA HealthCare, Mortsel, Belgium) installed in our institution. Parameters such as gender, age, in- or out-of-hospital CA, duration of CPR, cause of CA, and last sign of life were collected.

The CT protocol included a non-enhanced CT (neCT) of the head, a CT angiography (CTA) from the head to the groin, and an additional venous phase of the abdomen. All CT scans were performed with a 64-detector row CT scanner (Definition AS®, Siemens Healthineers, Forchheim, Germany).

The neCT of the head was done with 2×32 detector rows, 0.6-mm collimation, gantry rotation time of 1.0 s, and a pitch of 0.55. These scans were acquired in caudocranial direction. A tube current-time product of 370 mAs_{eff} was chosen at a tube voltage of 120 kV.

Thereafter, bolus tracking was used with a region of interest (ROI) placed in the ascending aorta. After reaching a threshold value of 140 HU, the scan was automatically started with a delay of 2 s. CT-angiograms (CTA) were performed with quality reference mAs (CARE Dose4D, Siemens) and a reference value of 120 mAs at a tube voltage of 120 kV. Scans were acquired in craniocaudal direction with 2×32 detector rows, 0.6-mm collimation, gantry rotation time of 0.5 s, and a pitch of 0.85.

With a delay of 30 s after completion of the CTA, a venous scan of the abdomen was started in craniocaudal direction with 2×32 detector rows, 0.6-mm collimation, gantry rotation time of 0.5 s, and a pitch of 0.6. CARE Dose4D with a reference value of 210 mAs and a tube current of 120 kV were used.

The contrast protocol included 110-ml intravenous contrast agent (Ultravist 370®, Bayer, Leverkusen, Germany) followed by a 30-ml saline chaser bolus, both of which were applied at a flow rate of 4 ml/s. Images were reconstructed with a slice thickness of 2 mm and 5 mm with an increment of 1 and 4 mm, respectively.

CT findings were determined corresponding to anatomical regions. Statistical analysis was performed with IBM SPSS Statistics (IBM SPSS Statistics, version 26, Armonk, United States of America). Statistical comparison was performed with chi-square (χ^2) test for categorical variables and Mann-Whitney U (MWU) test for continuous variables. Differences were regarded as significant at a two-sided $p < 0.05$.

Results

A total of 108 patients with CA and ROSC were scanned over 12 months. Eight patients were excluded because of a delayed WBCT after ROSC ($n = 5$), a traumatic cause of CA ($n = 2$), and an incomplete scan protocol ($n = 1$). In total, the study population included 100 patients of which 27 (27%) were female and 73 (73%) were male. Eighty-eight percent ($n = 88$) of the study population experienced the CA out of hospital and the remaining 22% ($n = 22$) in hospital. CA was most commonly due to heart and lung diseases (80%). Most men needed at least 20 min of CPR to gain ROSC (42.5%) whereas most women needed less than 10 min (44.4%). Additional details are shown in Table 1.

Patients with CA, who died in hospital were significantly older (mean rank of 57.02 versus 42.85, $p = 0.015$) and showed more often signs of global brain edema (12% versus 0%, $p = 0.001$) compared to those survived to discharge. Further information is shown in Table 2.

Early WBCT was successfully carried out in 100% of the patients with CA and ROSC after CPR. Once, patients were on the CT-table, a WBCT took on average 4 ± 2 min for a scan to complete. The mean Dose Length product of a WBCT was 2472.58 ± 704.0 mGy*cm.

Head and neck

Acute cranial pathologies were common in patients with CA and ROSC (15%). Twelve percent ($n = 12$) of the study population showed early global brain edema with an average gray-white-matter ratio (GWR) of 1.10. These patients needed at least 20 min CPR to gain ROSC and all of them died within their hospital stay. Acute ischemic stroke was found in 3% of the cases ($n = 3$). Further information is shown in Fig. 1.

Heart and coronaries

Most of the study population showed findings of heart failure, which were commonly located at the left ventricle and was associated with interstitial pulmonary edema. Arterial myocardial hypoperfusion was seen in 38% ($n = 38$) of the cases of which 65.79% ($n = 25$) were confirmed during cardiac catheterization. In total, 58% of the study population received a

Table 1 Patient demographics

	Female (<i>N</i> = 27)	Male (<i>n</i> = 73)	Total (<i>n</i> = 100)
Age, mean (SD)	70.85 (±13.3)	67.58 (± 12.37)	68.46 (± 12.57)
Cause of CA, <i>n</i> (%)			
Cardiac	10 (37.0)	46 (63.0)	56 (56.0)
CNS	2 (7.4)	1 (1.4)	3 (3.0)
Pulmonary	9 (33.3)	15 (20.5)	24 (24)
Sepsis	1 (3.7)	1 (1.4)	2 (2.0)
Hypovolemic shock	0 (0.0)	1 (1.4)	1 (1.0)
Toxic	0 (0.0)	2 (2.7)	2 (2.0)
Unknown	5 (18.5)	7 (9.6)	12 (12.0)
Duration of CPR (min), <i>n</i> (%)			
0–10	12 (44.4)	10 (13.7)	22 (22.0)
10–20	4 (14.8)	19 (26.4)	23 (23.0)
> 20	6 (22.2)	31 (42.5)	37 (37.0)
Unknown	5 (18.5)	13 (17.8)	18 (18.0)
Outcome, <i>n</i> (%)			
Discharged	12 (44.4)	34 (46.6)	46 (46.0)
Died in hospital	15 (55.6)	39 (53.4)	54 (54.0)

CA cardiac arrest, CNS central nervous system, CPR cardiopulmonary resuscitation, SD standard deviation, *N* number, min minutes

cardiac catheterization. Calcified plaques of the coronary arteries were seen in the vast majority of the patients and most commonly located at the left anterior descending artery with 72% (*n* = 72), followed by the left circumflex artery with 49% (*n* = 49) and the right coronary artery with 48% (*n* = 48). Additional information is shown in Fig. 1.

Vessels

Peripheral pulmonary embolism was observed in 10% (*n* = 10) of the cases of which 50% had an additional central embolism (*n* = 5).

Bleeding from the common femoral artery was detected in 4% (*n* = 4), all of them after an arterial puncture.

High-grade stenosis of the supra-aortic branches was observed in 19% (*n* = 19) and frequently located on both sides of the proximal carotid internal artery (47.4%). 21.05% (*n* = 4) of these patients had an additional occlusion of one carotid or one vertebral artery.

Aneurysms were observed in 9% of the cases (*n* = 9), which were frequently located in the infrarenal abdominal aorta (60%), followed by the aortic arch (20%), and thoracoabdominal aorta (10%). One patient showed bilaterally aneurysms of the internal iliac arteries (1%). No contained ruptured or ruptured aneurysms were seen.

In one patient, an acute dissection of the right femoral artery was detected (1%). Three patients had an asymptomatic chronic dissection of the infrarenal abdominal aorta. No deterioration of a chronic dissection, such as malperfusion syndrome was observed.

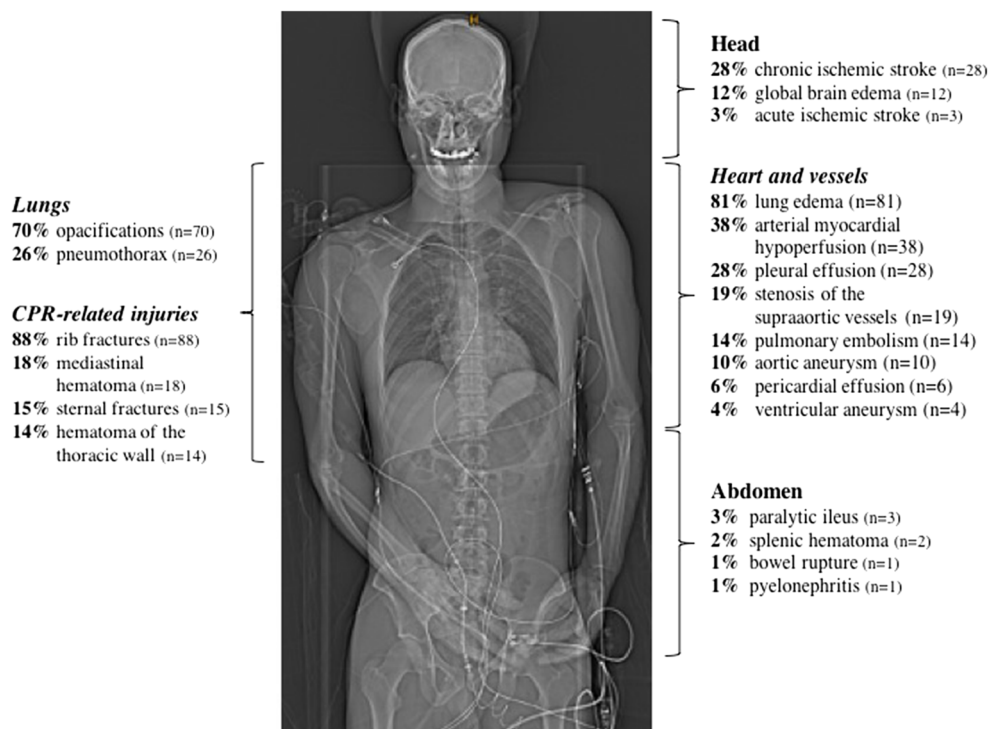
Lungs

In the study population, opacifications of the lungs were seen in 70% (*n* = 70) of the cases. 85.71% (*n* = 60) out of these were consolidations with lobar distribution and air bronchogram. 12.86% (*n* = 9) showed ground-glass infiltrates and 1.43% (*n* = 1) had interstitial infiltrates, both without signs of heart failure.

Table 2 Outcome according to selected pathologies

Outcome	Pneumothorax ¹	Tension-pneumothorax ¹	Brain edema ¹	Acute ischemic stroke ¹	Peripheral pulmonary embolism ¹	Central pulmonary embolism ¹	Acute abdominal pathologies ¹	Hemorrhage ¹
Death in hospital	15 (62.50)	1 (50.00)	12 (100)	2 (66.67)	6 (60.00)	3 (60.00)	6 (85.71)	4 (100)
Discharged	9 (37.50)	1 (50.00)	0 (0.00)	1 (33.33)	4 (40.00)	2 (40.00)	1 (14.29)	0 (0.00)
¹ <i>n</i> (%)								

Fig. 1 Overview of findings based on anatomic location



The opacifications were frequently located in the lower lobes and dorsal segments of the upper lobes (77.03%) and interpreted to be suspected for aspiration pneumonia. Other types and distributed infiltrates were seen less often (22.97%).

Bronchial cuffing, subpleural fluid collection, and septal thickening were seen in 59% of the cases ($n = 59$) and were interpreted as interstitial edema. Bilaterally, perihilar ground glass infiltrates were interpreted as alveolar edema and seen in 22% of the patients ($n = 22$).

A pneumothorax was detected in 26% ($n = 26$) of which 7.69% had a tension pneumothorax ($n = 2$). All pneumothoraces were associated with rib fractures.

Pulmonary contusion was shown in 16% ($n = 16$) of the study population, which manifested ground glass-infiltrates located ventral and subpleural in both upper lobes and in the middle lobe.

Malpositioned endobronchial tubes were detected in 20% ($n = 20$) of the study population.

Abdomen

Pathologies of the abdomen were seen in 10% ($n = 10$) of the study population. Three percent ($n = 3$) of the patients showed a paralytic small bowel ileus; in another 2% ($n = 2$), subcapsular splenic hematomas were observed, and 1% ($n = 1$) had a duodenal perforation with free intraabdominal fluid and gas.

Apart from pyelonephritis in 1% ($n = 1$) and renal infarction in another 1% ($n = 1$) of the cases, no further acute renal pathology was detected. One percent ($n = 1$) of the study population showed free intraperitoneal gas without detectable bowel perforation, which was interpreted as an extension of mediastinal emphysema caused by a large pneumothorax. Another 1% ($n = 1$) of the cases showed unspecific mesenteric lymphadenitis.

Musculoskeletal

Ninety-three percent ($n = 93$) of patients were resuscitated manually and 7% ($n = 7$) mechanically (AutoPulse, Zoll Circulation, Chelmsford, USA). With an incidence of 93% ($n = 93$), CPR-related injuries were very frequent. Rib fractures were seen in 88% ($n = 88$), most common bilaterally located and serially fractured (Table 3). The sternal fracture was detected in 15% ($n = 15$), which were most frequently located in the cranial and the middle part of the sternum with 88.67%. A sternal fracture was commonly detected in men (80%) and older patients with a mean age of 70.27 ± 12.62 years.

Mediastinal hematomas were detected in 18% ($n = 18$) and were associated with a sternal fracture in 22.2%. Mediastinal emphysema was seen in 7% ($n = 7$). Hematomas of the thoracic wall were detected in 14% ($n = 14$) and always combined with one or more dislocated rib fractures. The longer the resuscitation had to be carried out, the more frequent CPR-related injuries were detectable (Tables 4 and 5).

Table 3 Number and location of CPR-related rib fractures

	Female (<i>n</i> = 24)	Male (<i>n</i> = 64)	Total (<i>n</i> = 88)
Age	72.17 (± 12.17) ¹	68.39 (± 12.11) ¹	69.42 (± 12.40) ¹
Location, <i>n</i> (%)			
Right	2 (8.33) ²	2 (3.12) ²	4 (4.54) ²
Left	3 (12.50) ²	3 (4.69) ²	6 (6.81) ²
Bilateral	19 (79.17) ²	59 (92.19) ²	78 (88.65) ²
Number of fractures, <i>n</i> (%)			
< 3	0 (0.0) ²	6 (9.37) ²	6 (6.82) ²
3–6	9 (37.50) ²	10 (15.63) ²	19 (21.59) ²
6–9	5 (20.83) ²	21 (32.81) ²	26 (29.55) ²
> 9	10 (41.67) ²	13 (142.19) ²	37 (42.04) ²

¹ Mean (standard deviation)² *n* (%)

Discussion

The study results have shown that acute pathologies after CA and successful resuscitation are common and not only located in the chest. If assessed with a standard procedure of plain chest radiography (CXR), ultrasound (US) and focal imaging, these pathologies can be missed or detected too late. Data on the effectivity of an early WBCT compared to a standard procedure with CXR, US, and focal CT-imaging is not available for patients with CA. But data on multiple trauma patients showed an early WBCT to be more effective compared to a standard procedure with plain radiography, US, and focal CT-imaging in finding relevant pathologies for treatment [5]. If patients with CA have multiple pathologies with relevance for treatment similar to multiple trauma patients, a WBCT should also be more effective as a standard procedure with CXR, US, and focal CT-imaging for patients with CA and ROSC.

Global brain edema (12%), acute ischemic stroke (3%), pulmonary embolism (10%), acute abdominal pathologies such as paralytic ileus, splenic hematomas, duodenal perforation, and pyelonephritis (7%) as well as bleeding (4%) were detected in 26% of the study population. These pathologies were assessed to be of additional value because they would

Table 5 Correlation between CPR, number of fractured ribs, and sternal fracture

Duration of CPR ¹	> 9 ²	6–9 ²	3–6 ²	< 3 ²	Sternum ³
> 20	17	9	6	2	8
10–20	10	8	3	1	1
< 10	6	5	7	1	4
Unknown	4	4	3	2	2

¹ cardiopulmonary resuscitation in minutes² Rib fractures³ Sternal fracture

otherwise be diagnosed delayed or even missed without an early WBCT. According to current guidelines CT is recommended for these pathologies [10–13].

Also, an early WBCT can have additional value for patients with CA due to an acute aortic syndrome or an intracranial hemorrhage because of its high sensitivity and specificity for these pathologies [14–16]. The exclusion of intracranial hemorrhage and thoracic or abdominal bleeding with CT is important before starting anticoagulation [13].

The study demonstrates that CPR-related pathologies of treatment relevance such as pneumothorax due to dislocated rib fractures are frequent. CXR is known to underestimate such CPR-related injuries [17]. Whereas, MDCT has a higher sensitivity and specificity to detect these injuries in comparison to CXR [18]. Dunham et al. published a rib fracture rate up to 85% of resuscitated CA patients, which is similar to our results. But in his study, a twofold incidence of sternal fractures is reported [4]. This variability in CT-detected sternal fractures after CPR is well known. A review by Hoke et al. and more recent studies show wide variability in sternal fractures from 1 to 43% [9, 19–22]. The causes of this variability stay unknown and are likely to be multifactorial [4].

The reported findings demonstrate that global brain edema is common especially when prolonged CPR was necessary. Naples et al. published global brain edema rates up to 35% for resuscitated patients with non-traumatic CA on CT. The

Table 4 CPR-related injuries according to duration of CPR

Duration of CPR ¹	Pneumothorax ²	Tension-pneumothorax ²	Sternal fracture ²	Mediastinal hematoma ²	Chest wall hematoma ²	Lung contusion ²	Outcome ^{2,3}
> 20	11 (45.83)	2 (100)	8 (53.33)	8 (44.44)	7 (50.00)	10 (62.50)	25 (46.30)
10–20	5 (20.83)	0 (0.00)	1 (6.67)	6 (33.33)	1 (7.14)	1 (6.25)	14 (25.93)
< 10	3 (12.50)	0 (0.00)	4 (26.67)	2 (11.11)	3 (21.43)	2 (12.50)	7 (12.96)
Unknown	5 (20.83)	0 (0.00)	2 (13.33)	2 (11.11)	3 (21.43)	3 (18.75)	8 (14.81)

¹ Cardiopulmonary resuscitation in minutes² *n* (%)³ Death in hospital

discrepancy of the results is probably due to selection processes because only 22% of the study population with a high pretest probability for brain pathologies underwent a cranial CT [23]. The results of our study showed a GWR of 1.10 is associated with 100% patient mortality. This result is consistent with the previously published data [24–27].

Regurgitation and pulmonary aspiration of gastric contents are known risk factors for patients with CA and CPR [28–30]. The reported results demonstrate high rates for opacifications in the lower lobes and dorsal segments of the upper lobes, which were interpreted as consequence of regurgitation and pulmonary aspiration [31]. Comparable data on the diagnosis of regurgitation and pulmonary aspiration in patients with CA and CPR is rare. A single-center study with 182 patients published an incidence of 20% after CA and CPR [32]. But the diagnosis in this study is based on inspection during the intubation process. The CT on the other hand can visualize the entire tracheobronchial system including the lungs and should be more sensitive than sight evaluation during intubation. But data on comparison both diagnostic tests do not exist.

With 32% extracardiac causes of the CA were common in the study population. In these cases, a dedicated coronary CTA could help to rule out an obstructive coronary artery disease (CAD) as underlying pathology, because of its high sensitivity to rule out a CAD [33]. The 2 × 32-row single-source study scanner cannot perform a coronary CTA of the entire heart within one cardiac cycle, which makes it susceptible to arrhythmias or ventricular tachycardias and leads to severe motion artifacts with impaired image quality [34]. Expecting obstructive CAD, arrhythmias, and ventricular tachycardias in the study population, the WBCT does not include a dedicated coronary CTA. But modern dual-energy source MDCT with wide-area detectors and iterative reconstruction are less susceptible to arrhythmias or tachycardias and could provide a useable coronary angiogram in this population.

Conclusion

Early WBCT is feasible in patients with CA and ROSC after CPR. Acute pathologies are not limited to the thorax but can also be found in the head and abdomen, which can be easily detected by WBCT. Extracardiac causes of a CA are common and can be illustrated by a WBCT. Therefore, a WBCT should be recommended in the post-cardiac arrest care of patients with non-traumatic CA and ROSC after CPR.

Compliance with ethical standards

Conflict of interest The authors declare that they have no conflict of interest.

References

- Hayashi M, Shimizu W, Albert CM (2015) The spectrum of epidemiology underlying sudden cardiac death. *Circ Res* 116:1887–1906. <https://doi.org/10.1161/CIRCRESAHA.116.304521>
- Bergum D, Nordseth T, Mjølstad OC, Skogvoll E, Haugen BO (2015) Causes of in-hospital cardiac arrest - incidences and rate of recognition. *Resuscitation* 87:63–68. <https://doi.org/10.1016/j.resuscitation.2014.11.007>
- Katritsis DG, Athens Euroclinic, Greece, and Beth Israel Deaconess Medical Center, Harvard Medical School, Boston, MA, USA, Gersh BJ et al (2016) A clinical perspective on sudden cardiac death. *Arrhythmia & Electrophysiology Review* 5:177. <https://doi.org/10.15420/aer.2016:11:2>
- Dunham GM, Perez-Girbes A, Bolster F, Sheehan K, Linnau KF (2017) Use of whole body CT to detect patterns of CPR-related injuries after sudden cardiac arrest. *Eur Radiol* 33:39–36. <https://doi.org/10.1007/s00330-017-5117-0>
- Jiang L, Ma Y, Jiang S et al (2014) Comparison of whole-body computed tomography vs selective radiological imaging on outcomes in major trauma patients: a meta-analysis. *Scandinavian Journal of Trauma, Resuscitation and Emergency Medicine* 22:54. <https://doi.org/10.1186/s13049-014-0054-2>
- Callaway CW, Donnino MW, Fink EL, et al (2015) Part 8: post-cardiac arrest care: 2015 American Heart Association guidelines update for cardiopulmonary resuscitation and emergency cardiovascular care. *Circulation*. 132(suppl 2):S465–S482. <https://doi.org/10.1161/CIR.0000000000000262>
- Nolan JP, Soar J, Cariou A, Cronberg T, Moulart VRM, Deakin CD, Bottiger BW, Friberg H, Sunde K, Sandroni C (2015) European resuscitation council and European Society of Intensive Care Medicine 2015 guidelines for post-resuscitation care. *Intensive Care Med* 41:2039–2056. <https://doi.org/10.1007/s00134-015-4051-3>
- Choi SJ, Kim HS, Kim EY, Choi HY, Cho J, Yang HJ, Kim YS (2014) Thoraco-abdominal CT examinations for evaluating cause of cardiac arrest and complications of chest compression in resuscitated patients. *Emerg Radiol* 21:485–490. <https://doi.org/10.1007/s10140-014-1218-0>
- Kashiwagi Y, Sasakawa T, Tampo A, Kawata D, Nishiura T, Kokita N, Iwasaki H, Fujita S (2015) Computed tomography findings of complications resulting from cardiopulmonary resuscitation. *Resuscitation* 88:86–91. <https://doi.org/10.1016/j.resuscitation.2014.12.022>
- Wijdicks EFM, Sheth KN, Carter BS, Greer DM, Kasner SE, Kimberly WT, Schwab S, Smith EE, Tamargo RJ, Wintermark M (2014) Recommendations for the management of cerebral and cerebellar infarction with swelling: a statement for healthcare professionals from the American Heart Association/American Stroke Association. *Stroke* 45:1222–1238. <https://doi.org/10.1161/01.str.0000441965.15164.d6>
- Powers WJ, Rabinstein AA, Ackerson T, Adeoye OM, Bambakidis NC, Becker K, Biller J, Brown M, Demaerschalk BM, Hoh B, Jauch EC, Kidwell CS, Leslie-Mazwi TM, Ovbiagele B, Scott PA, Sheth KN, Southerland AM, Summers DV, Tirschwell DL, American Heart Association Stroke Council (2018) 2018 guidelines for the early management of patients with acute ischemic stroke: a guideline for healthcare professionals from the American Heart Association/American Stroke Association. *Stroke* 49:1–e110. <https://doi.org/10.1161/STR.0000000000000158>
- Konstantinides SV, Torbicki A, Agnelli G et al (2014) 2014 ESC guidelines on the diagnosis and management of acute pulmonary embolism. *Eur Heart J* 35:3033–69–3069a–3069k. <https://doi.org/10.1093/eurheartj/ehu283>

13. Spahn DR, Bouillon B, Cerny V et al (2019) The European guideline on management of major bleeding and coagulopathy following trauma: fifth edition. *Crit Care* 23:74. <https://doi.org/10.1186/s13054-019-2347-3>
14. Doğan H, de Roos A, Geleijns J et al (2015) The role of computed tomography in the diagnosis of acute and chronic pulmonary embolism. *Diagn Interv Radiol* 21:307–316. <https://doi.org/10.5152/dir.2015.14403>
15. Aygun N, Masaryk TJ (2002) Diagnostic imaging for intracerebral hemorrhage. *Neurosurg Clin N Am* 13:313–34–vi
16. Sebastia C, Pallisa E, Quiroga S et al (1999) Aortic dissection: diagnosis and follow-up with helical CT. *Radiographics* 19:45–60–quiz 149–50. <https://doi.org/10.1148/radiographics.19.1.g99ja0945>
17. Lederer W, Mair D, Rabl W, Baubin M (2004) Frequency of rib and sternum fractures associated with out-of-hospital cardiopulmonary resuscitation is underestimated by conventional chest X-ray. *Resuscitation* 60:157–162. <https://doi.org/10.1016/j.resuscitation.2003.10.003>
18. Cho SH, Kim EY, Choi SJ, Kim YK, Sung YM, Choi HY, Cho J, Yang HJ (2013) Multidetector CT and radiographic findings of lung injuries secondary to cardiopulmonary resuscitation. *Injury* 44:1204–1207. <https://doi.org/10.1016/j.injury.2012.10.004>
19. Hoke RS, Chamberlain D (2004) Skeletal chest injuries secondary to cardiopulmonary resuscitation. *Resuscitation* 63:327–338. <https://doi.org/10.1016/j.resuscitation.2004.05.019>
20. Kim MJ, Park YS, Kim SW, Yoon YS, Lee KR, Lim TH, Lim H, Park HY, Park JM, Chung SP (2013) Chest injury following cardiopulmonary resuscitation: a prospective computed tomography evaluation. *Resuscitation* 84:361–364. <https://doi.org/10.1016/j.resuscitation.2012.07.011>
21. Kim EY, Yang HJ, Sung YM, Cho SH, Kim JH, Kim HS, Choi HY (2011) Multidetector CT findings of skeletal chest injuries secondary to cardiopulmonary resuscitation. *Resuscitation* 82:1285–1288. <https://doi.org/10.1016/j.resuscitation.2011.05.023>
22. Hellevuo H, Sainio M, Nevalainen R, Huhtala H, Olkkola KT, Tenhunen J, Hoppu S (2013) Deeper chest compression – more complications for cardiac arrest patients? *Resuscitation* 84:760–765. <https://doi.org/10.1016/j.resuscitation.2013.02.015>
23. Naples R, Ellison E, Brady WJ (2009) Cranial computed tomography in the resuscitated patient with cardiac arrest. *Am J Emerg Med* 27:63–67. <https://doi.org/10.1016/j.ajem.2008.01.014>
24. Scheel M, Storm C, Gentsch A et al (2013) The prognostic value of gray-white-matter ratio in cardiac arrest patients treated with hypothermia. *Scandinavian Journal of Trauma, Resuscitation and Emergency Medicine* 21:23. <https://doi.org/10.1186/1757-7241-21-23>
25. Lee YH, Oh YT, Ahn HC, Kim HS, Han SJ, Lee JJ, Lee TH, Seo JY, Shin DH, Ha SO, Park SO (2016) The prognostic value of the grey-to-white matter ratio in cardiac arrest patients treated with extracorporeal membrane oxygenation. *Resuscitation* 99:50–55. <https://doi.org/10.1016/j.resuscitation.2015.11.009>
26. Choi SP, Park HK, Park KN, Kim YM, Ahn KJ, Choi KH, Lee WJ, Jeong SK (2008) The density ratio of grey to white matter on computed tomography as an early predictor of vegetative state or death after cardiac arrest. *Emerg Med J* 25:666–669. <https://doi.org/10.1136/emj.2007.053306>
27. Metter RB, Rittenberger JC, Guyette FX, Callaway CW (2011) Association between a quantitative CT scan measure of brain edema and outcome after cardiac arrest. *Resuscitation* 82:1180–1185. <https://doi.org/10.1016/j.resuscitation.2011.04.001>
28. Lawes EG, Baskett PJ (1987) Pulmonary aspiration during unsuccessful cardiopulmonary resuscitation. *Intensive Care Med* 13:379–382
29. Oschatz E, Wunderbaldinger P, Sterz F, Holzer M, Kofler J, Slatin H, Janata K, Eisenburger P, Bankier AA, Lagner AN (2001) Cardiopulmonary resuscitation performed by bystanders does not increase adverse effects as assessed by chest radiography. *Anesth Analg* 93:128–133
30. Axelsson A, Herlitz J, Ekström L, Holmberg S (1996) Bystander-initiated cardiopulmonary resuscitation out-of-hospital. A first description of the bystanders and their experiences. *Resuscitation* 33:3–11
31. Franquet T, Giménez A, Rosón N, Torrubia S, Sabaté JM, Pérez C (2000) Aspiration diseases: findings, pitfalls, and differential diagnosis. *Radiographics* 20:673–685. <https://doi.org/10.1148/radiographics.20.3.g00ma01673>
32. Virkkunen I, Ryyänen S, Kujala S, Vuori A, Piilonen A, Kääriä JP, Kähärä V, Pettilä V, Yli-Hankala A, Silfvast T (2007) Incidence of regurgitation and pulmonary aspiration of gastric contents in survivors from out-of-hospital cardiac arrest. *Acta Anaesthesiol Scand* 51:202–205. <https://doi.org/10.1111/j.1399-6576.2006.01229.x>
33. Rossi A, Dharampal A, Wragg A, Davies LC, van Geuns RJ, Anagnostopoulos C, Klotz E, Kitslaar P, Broersen A, Mathur A, Nieman K, Hunink MGM, de Feyter PJ, Petersen SE, Pugliese F (2014) Diagnostic performance of hyperaemic myocardial blood flow index obtained by dynamic computed tomography: does it predict functionally significant coronary lesions? *Eur Heart J Cardiovasc Imaging* 15:85–94. <https://doi.org/10.1093/ehjci/jet133>
34. Machida H, Tanaka I, Fukui R, Shen Y, Ishikawa T, Tate E, Ueno E (2015) Current and novel imaging techniques in coronary CT. *Radiographics* 35:991–1010. <https://doi.org/10.1148/rg.2015140181>

Publisher's note Springer Nature remains neutral with regard to jurisdictional claims in published maps and institutional affiliations.